

## Feline Positioning Guide

- Always remember that sensor safety comes first. You always want to protect your sensor from moisture by using a sensor sheath.
- Wrap your sensor in vet wrap to give it a slight cushion, this will also give you some traction (the sensor will stay in place better). Be careful to only wrap the sensor, and you want to unwrap it when done. Cutting the vet wrap off can cause damage to the sensor and the cord.
- Think of the tube head as the sun. At noon you don't cast a shadow, whereas at 3 o'clock you cast a very long shadow. X-rays are just like that! If your angle is too long your teeth will appear long (elongated) and if your angle is too short then your teeth will appear short and stubby (foreshortened).
- When your teeth are elongated you actually can create false pathology, and when they're foreshortened you can actually hide pathology.

## Introduction

Think of dental radiographs as a “shadow” of the root of the tooth\*

You need the sensor to “catch” the shadow\*

The x-ray generator is like the sun in the sky, casting that shadow onto the sensor



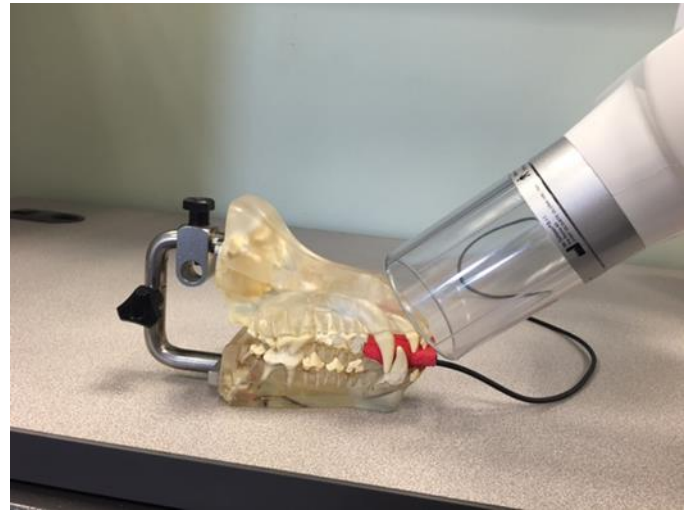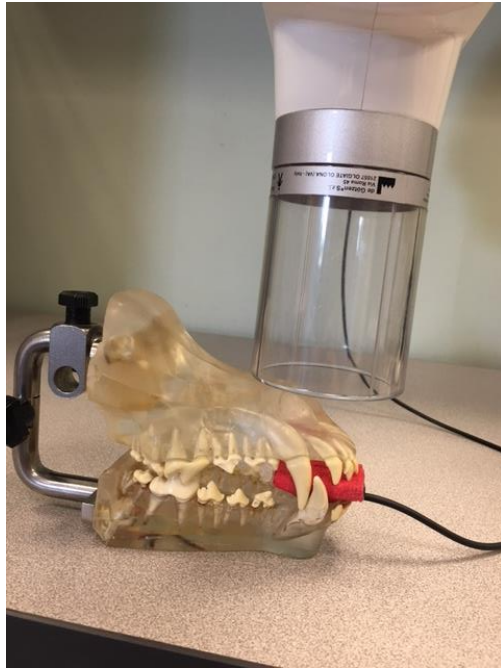
When the sun is high up in the sky, around noon, your shadow is going to be foreshortened, or smaller than the actual object.



When the sun is setting and low in the sky, your shadow is going to be elongated, or much larger than the actual object.

## Tube Head Positioning

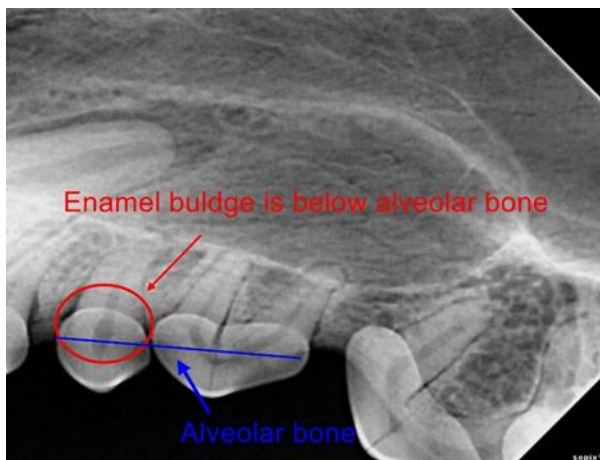
**\*Remember: The tube head is like the sun in the sky, it's position determines the length of the "shadow" \***



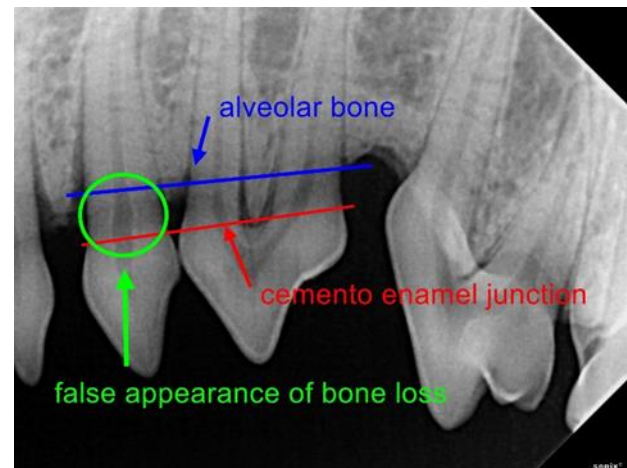
Having the tube head too high up (sun in sky at noon) will cause the radiograph to be foreshortened. In that case, lower the "sun".

Having the tube head too low, (sun at 6pm) will cause the radiograph to be elongated. In that case, raise the "sun".

### Example:



### Example:

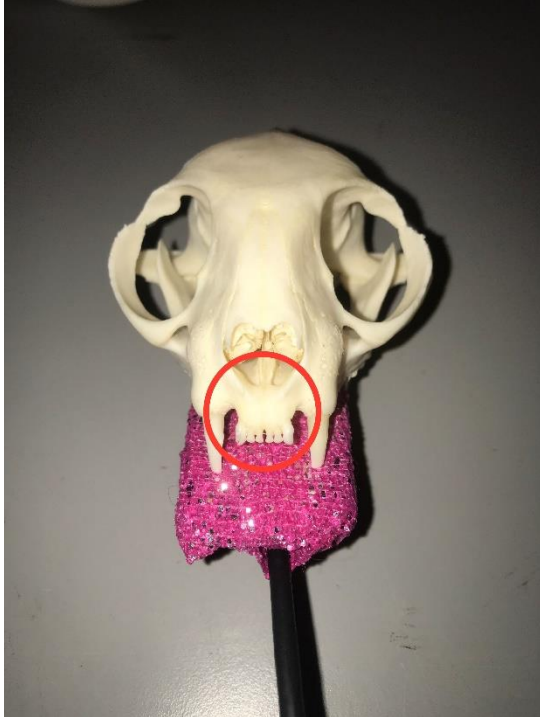

**Sensor placement (Maxilla)**

**Patient is sternal**

**\*Cord is always coming out of the mouth\***

**Incisors**

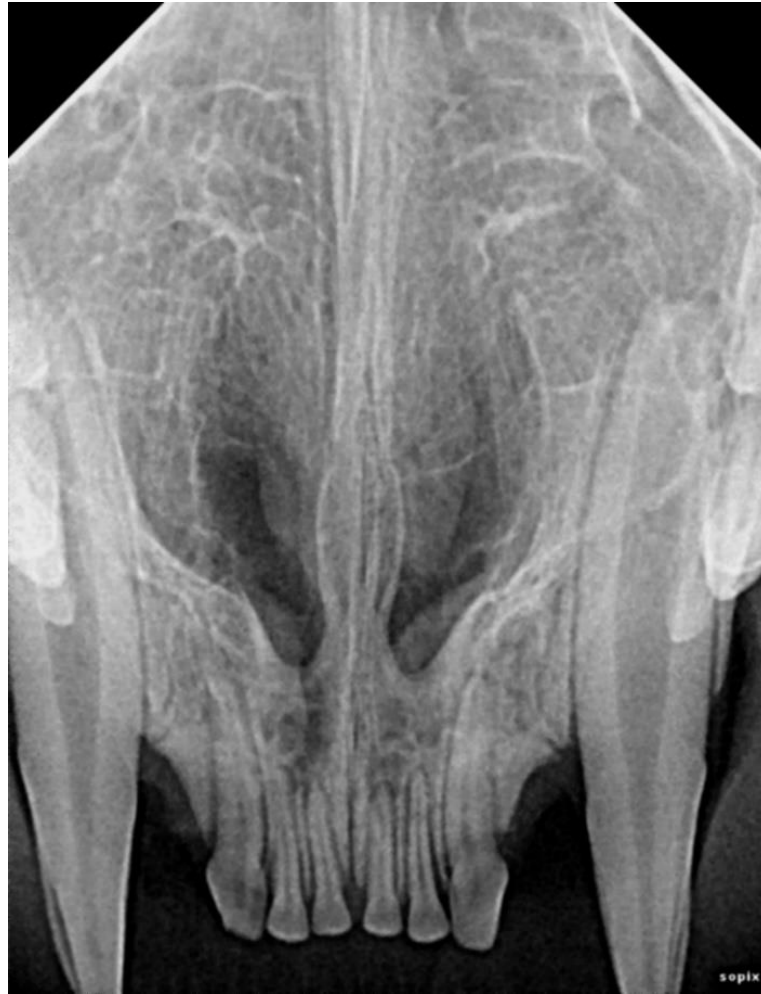

Sensor is flat against the palate. You can stabilize the sensor with gauze if needed. Sensor is centralized and not favoring any sides of the mouth. You want to aim your tube head to roots of the teeth, where the circle is.



You'll want to point your tube head toward the tip of the nose. You'll want your angle at an 80 degree angle or 1 o'clock.

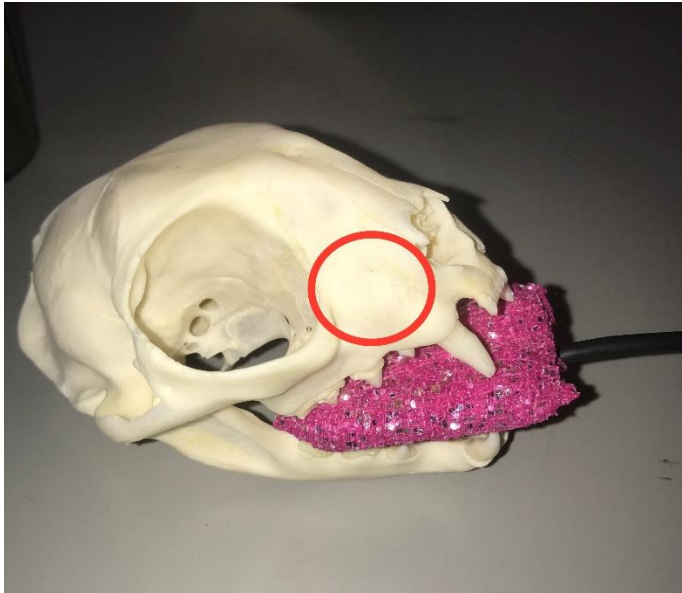
**Example:**




- **Note that the incisors are in the center of the x-ray and they aren't foreshortened or elongated.**
- **Although we were able to capture the canines, this is NOT diagnostic.**



## Canines

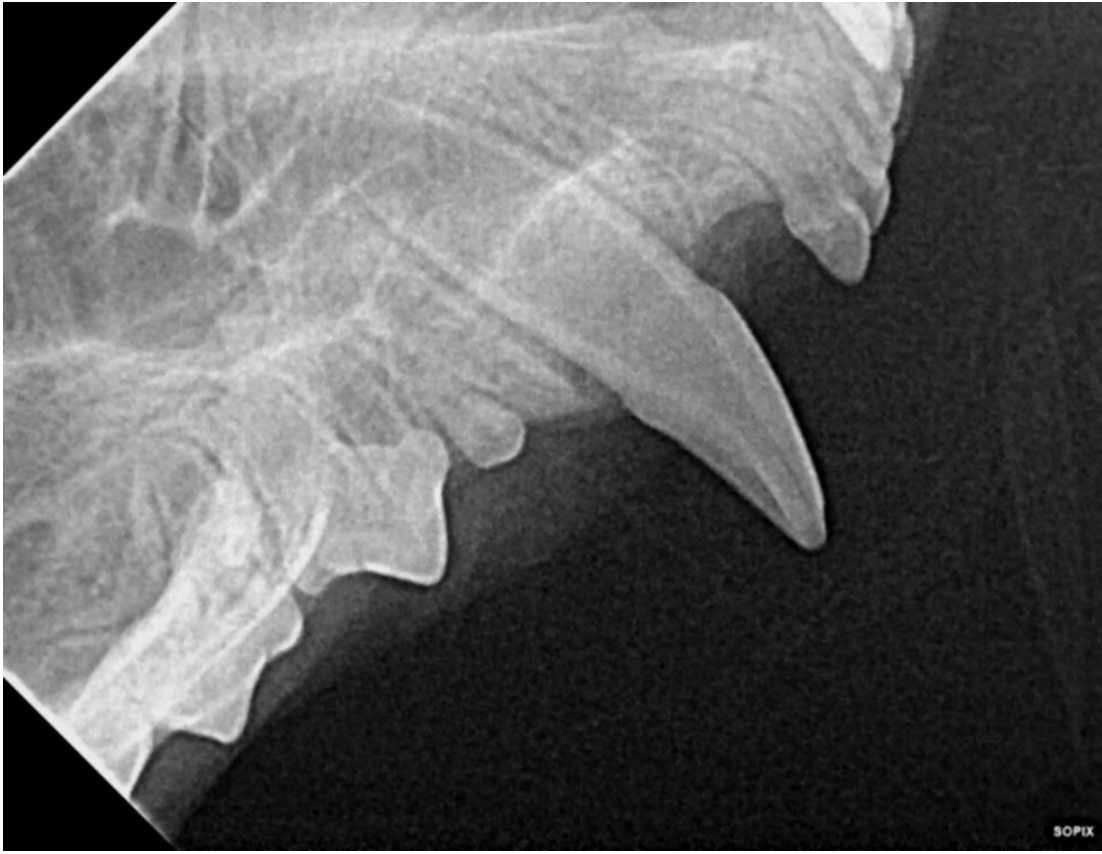

To place the sensor, move it laterally and caudally from your incisor shot. You want the sensor to capture as much as possible, so push the sensor farther into the mouth but keep the rostral portion of the sensor on the canine tooth.



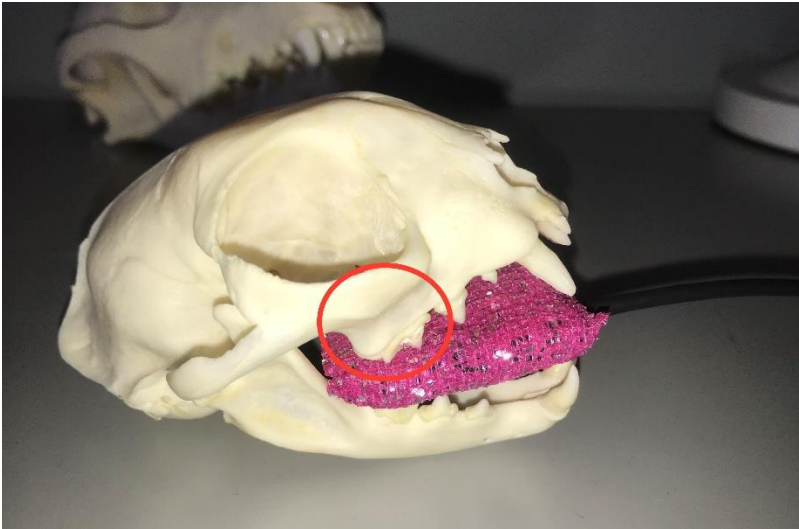
Angle your tube head from the side, not the front. You'll want to shoot your radiograph with the angle as your incisor, 80 degrees or 1 o'clock. And aim your tube head behind the nose and to the side.

**Example:**

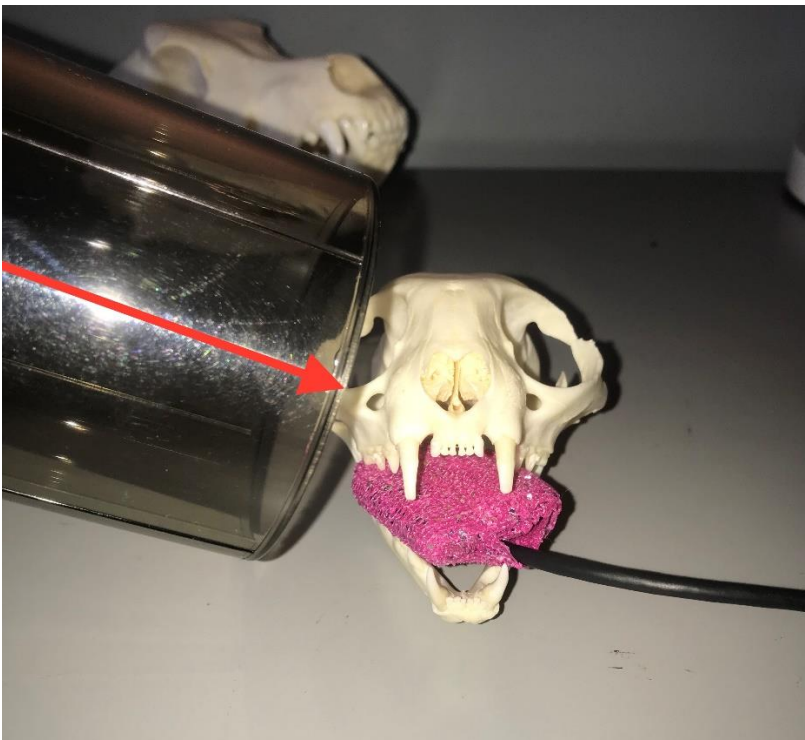


- **Note that we were able to capture the entire tooth, from the tip of the crown to the apex of the root.**
- **We are also able to see the second and third premolar in this image**

## Carnassial (Fourth Premolar)

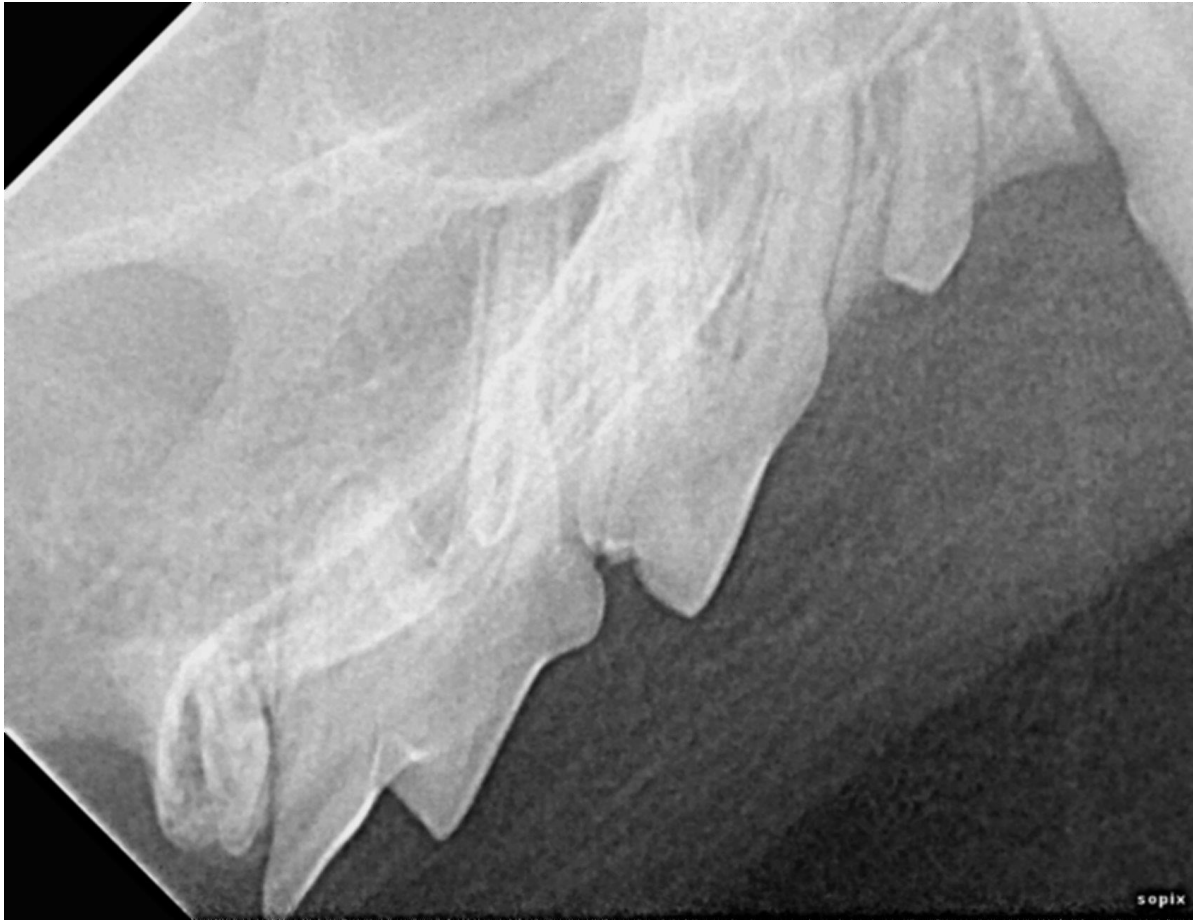

To place your sensor move it caudally as far back as the anatomy will allow you.



Cats have a more pronounced zygomatic arch than dogs. As far as your angle you'll want to purposely elongate your image in order to move the zygomatic arch out of the way. You'll aim your tube head at the roots of the upper fourth premolar/first molar. The angle you would have to position your tube head would be a 45 degree angle or 3 o'clock

**Example:**



- **We purposely elongated the teeth in order to get the zygomatic arch out of the way**




## **Sensor placement (Mandible)**

**Patient is dorsal**

### **Lower Incisors/Canines**

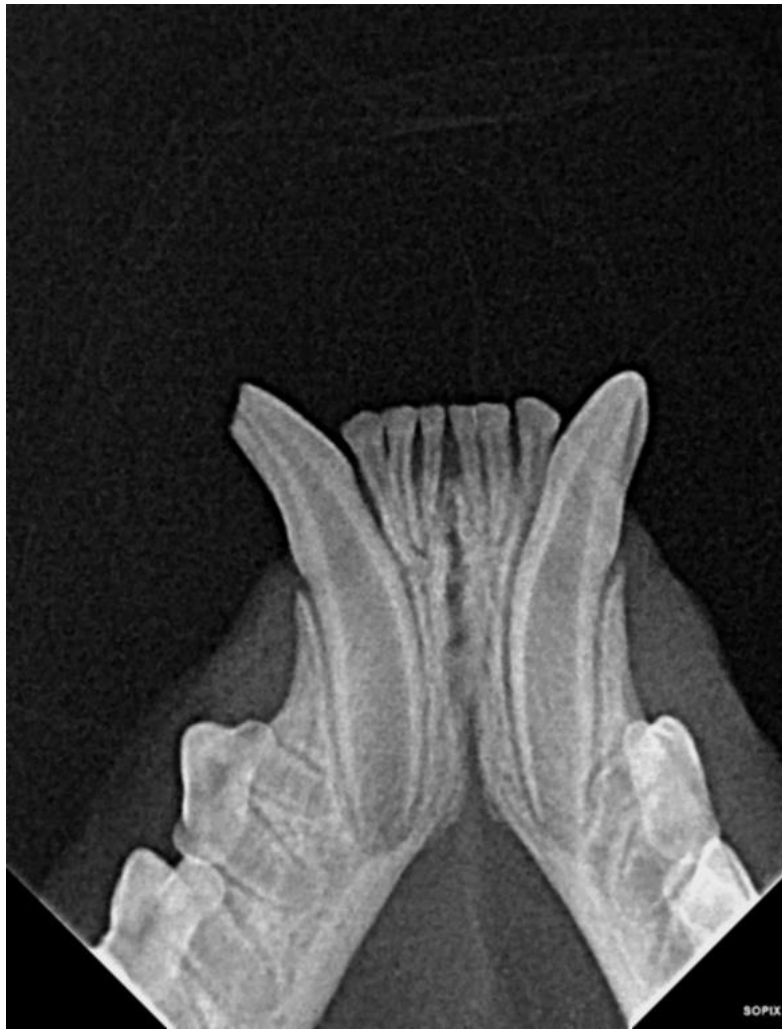

Cats are much smaller than dogs, you'll be able to fit both the incisors and the canines in one image. To place the sensor, you'll want it to be centralized again. You'll also want the rostral edge of the sensor to be as close to the tips as possible.



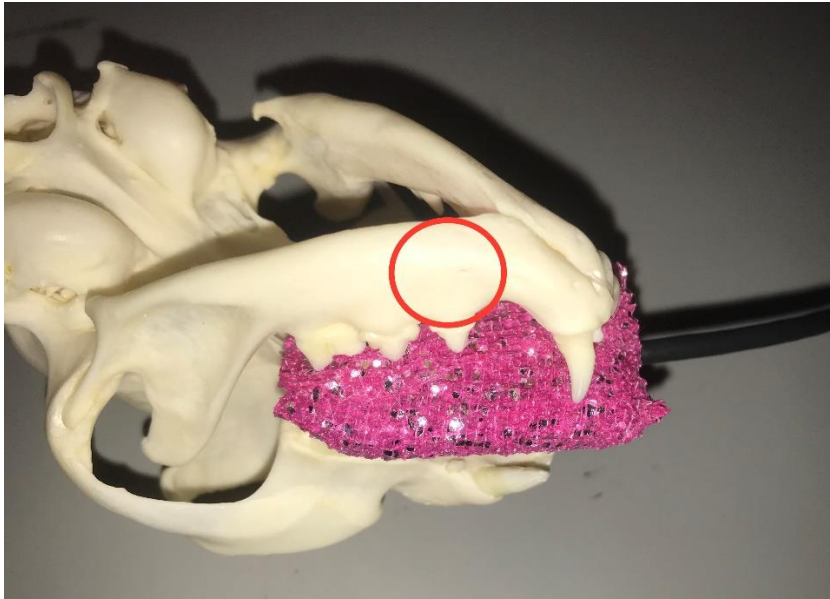
You'll want to have the same angle as your maxillary incisors. So about 80 degrees or 1 o'clock. And you'll want to aim your tube head at the roots of the canines

**Example:**



- **Note that we were able to get both the canines and incisors**

**Lower Premolars**

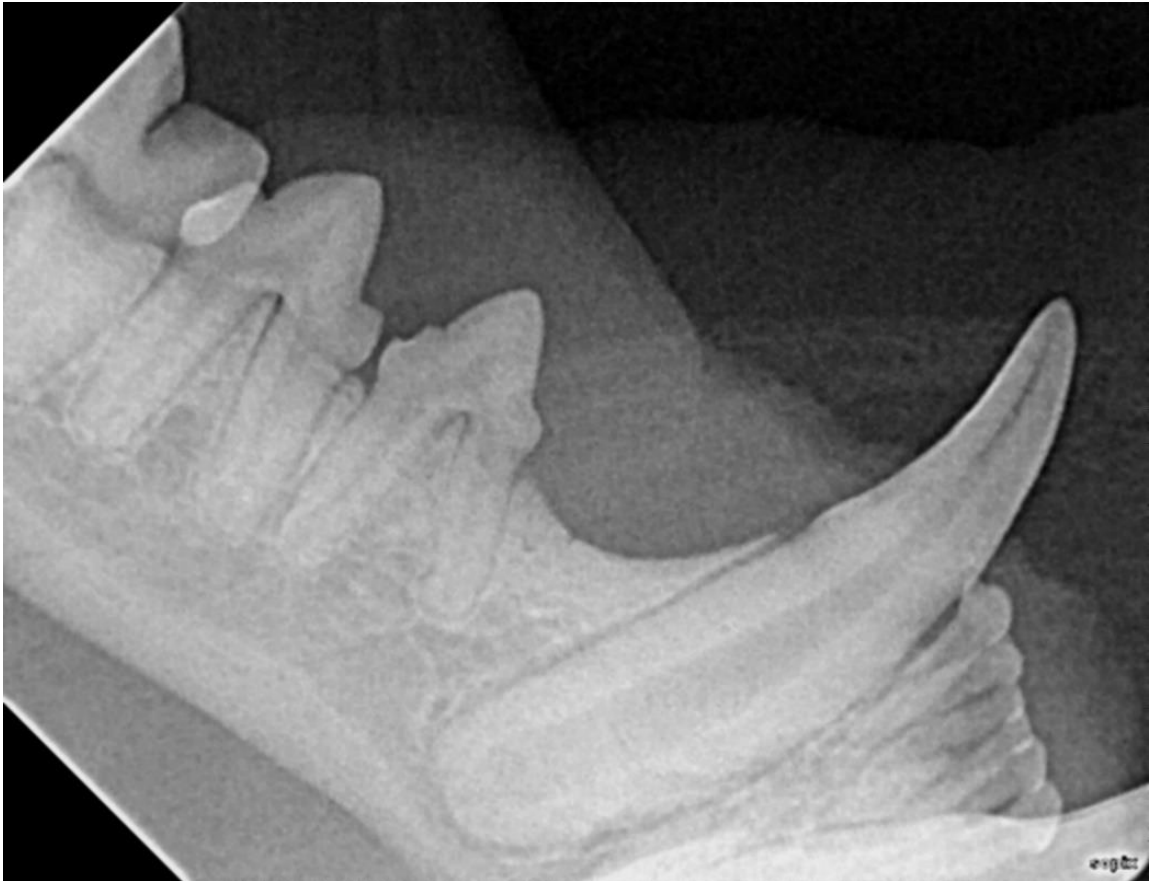

To place your sensor angle it to the side, going with the anatomy.



Move your tube head to the side, not the front. Angle the tube head at about 60 degrees, so about 2 o'clock.

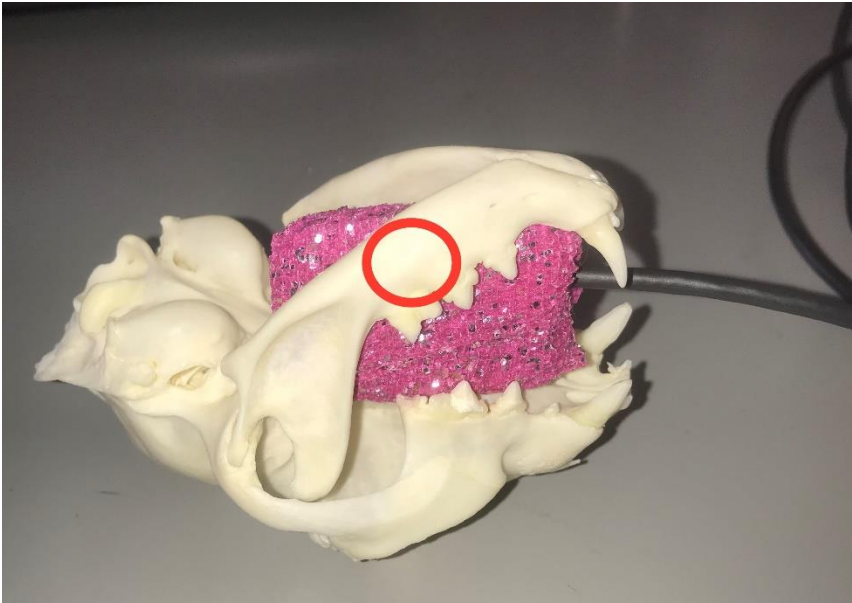
**Example:**




- **Notice that we were only able to get the third and fourth premolar, as well as a lateral view of the canine and NOT the first molar**



## Lower First Molar

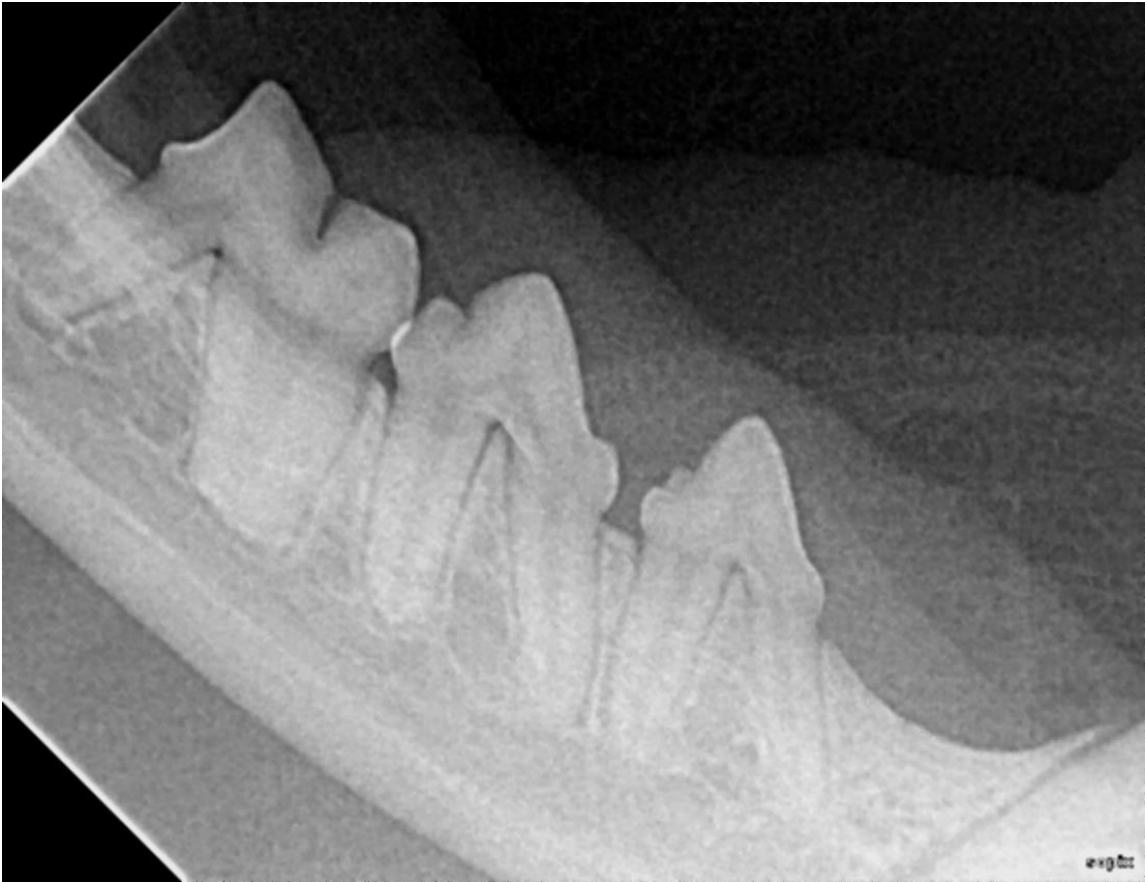

To place your sensor you're going to oblique it and slide it parallel to the mandible. In smaller cats you won't be able to place your sensor horizontal, for those smaller patients place your sensor vertical.



Position your tube head straight on to the roots of your molar. Your tube head will end up being close to a 45 degree angle.

**Example:**



- **Notice that in this image we were able to get all three cheek teeth, typically you wont be able to see that in larger cats.**